短　報

Mixed Infection of Malariae Malaria and Falciparum Malaria

Kenji OHNISHI[1)], Yasuyuki KATO[1)] & Shigeyuki KANO[2)]

[1)]Department of Infectious Diseases, Tokyo Metropolitan Bokutoh General Hospital,

[2)]Department of Appropriate Technology Development and Transfer, Research Institute, International Medical Center of Japan

（Received：October 10, 2000）

（Accepted：Nobember 21, 2000）

Key words：　*Plasmodium malariae, Plasmodium falciparum*

〔J.J.A. Inf. D. 75：219～221, 2001〕

Introduction

People living in or traveling to or from tropical and subtropical areas may by exposed to endemic parasites such as *Plasmodium* spp, *Giardia lamblia*, and a variety of soil-transmitted helminths. Malaria, a disease caused by *Plasmodium* sp. infection, is not endemic to Japan, but the number of malaria patients has increased. Most involve falciparum malaria or vivax malaria. Cases of malariae malaria, especially in patients coinfected with falciparum malaria, are very rare[1,2)]. We treated a patient coinfected with malariae malaria and falciparum malaria, as reported below.

Case Report

A 36-year-old Indian man was admitted to our hospital on May 17, 2000, because of a 9-day of fever and 6 days of diarrhea. He reported he had never had malaria. He had been in Japan for 10 years, and had traveled in India from March 30 to April 28, 2000, then returned to Japan. In India, he visited New Delhi, Calcutta, and a Gaya suburb. On admission, his temperature was 40.2℃ and his consciousness alert. Lymph nodes were not palpable on the neck. Auscultation of the heart and lungs was unremarkable, and bowel sound was hyperactive. Routine laboratory examination revealed thrombocytopenia（platelet count : $5.5 \times 10^4/mm^3$）. Prothrombin time was 42.8%. The serum level of lactate dehydrogenase was 365 IU/*l*, aspartate aminotransferase 52 IU/*l*, and C-reactive protein 17.0mg/dl. Peripheral blood smears revealed *Plasmodium malariae* and *P. falciparum*（Fig. 1）. The parasitemia of *Plasmodium* sp. was 1.0%. Chest X-ray film revealed no abnormal findings. No pathogenic bacteria were cultured in blood or stool. He was treated with 5 ml of Quinimax®（2ml of Quinimax® contains 240.0mg of quinine, 6.6mg of quinidine, 1.7mg of cinchonine, and 1.7mg of cinchonidine, Sanofi Winthrop, France）in an intravenously drip May 17 and then oral administration of 4 tablets of Mephaquin®（1 tablet of Mephaquin® contains 250mg of meflo-

Correspondence to：Kenji OHNISHI

Department of Infectious Diseases, Tokyo Metropolitan Bokutoh General Hospital, 4-23-15 Kotobashi, Sumida City, Tokyo 130-8575, Japan

平成13年 3 月20日

Fig. 1 Microscopical findings in Giemsa-stained thin blood smears. A) Band form of *Plasmodium malariae* infected erythrocyte, and B) ring form of *P. falciparum* infected erythrocytes.

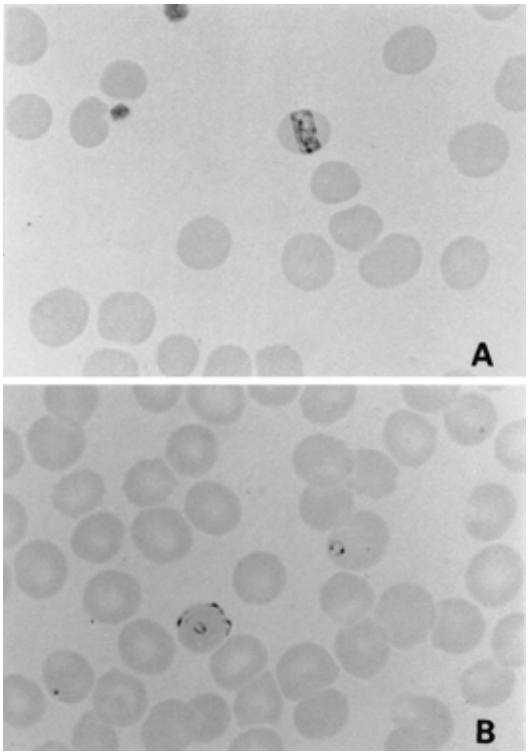

Table 1 Serum antibody titer against *Plasmodium* sp.

	P. malariae	*P. falciparum*	*P. vivax*	*P. ovale*
May 17, 2000	256	64	64	64
May 25, 2000	1,024	1,024	64	4
Positive control	64	256	256	64
Negative control	< 4	< 4	< 4	< 4

quine base, Mepha Ltd., Switzerland) May 18. Neither *P. malariae* nor *P. falciparum* were identified in his periperal blood smear since May 19. He was discharged on May 23, and no relapse of malariae malaria or falciparum malaria was identified. His serum antibody titer against *Plasmodium* sp. is shown in Table 1.

Discussion

Our patient was diagnosed with coinfection of *P. malariae* and *P. falciparum* by microscopic examination and serum antibody analysis. Malariae malaria has a spotty presence in tropical and subtropical areas[3], and this may explain why Japanese physicians are unfamiliar with the disease. Although mixed infection is rare, it is important to investigate whether other kinds of malaria coinfect in malaria patients. The number of patients with malaria will increase as more people travel to malaria-endemic regions. Japa-

nese physicians should familiarize themselves with malariae malaria and common types of malaria such as falciparum malaria and vivax malaria.

References

1) Ohtomo H：Patients with hyperpyrexia-overseas tourist hyperpyrexia. Asian Med J 1990；33：142–147.
2) Ohtomo H, Takeuchi T：Studies on current trend of imported malaria in Japan. Jpn J Trop Med 1998；26：151–156.
3) Gilles HR：Epidemiology of malaria. *In*：Gilles HM, Warrell DA, ed. Bruce-Chwatt's Essential Malariology, 3rd ed. Edward Arnold, London, 1993；124.

四日熱マラリアと熱帯熱マラリアの混合感染の１例

[1]東京都立墨東病院感染症科，[2]国立国際医療センター研究所適正技術開発・移転研究部

大西　健児[1]　加藤　康幸[1]　狩野　繁之[2]

平成13年３月20日